

# Evaluating the Diagnostic Accuracy of Tympanometry and High-Resolution CT in Otosclerosis: A Retrospective Comparative Study

Siddharth Manoj<sup>1</sup>, Advait Bhuran<sup>2</sup>, Rashmi Hansdah<sup>3</sup>, Vidhu Sharma<sup>4</sup>, Sarbesh Tiwari<sup>5</sup>, Kapil Soni<sup>6</sup>, Amit Goyal<sup>7</sup>

Received on: 13 March 2025; Accepted on: 31 March 2025; Published on: 07 April 2025

## ABSTRACT

**Background:** Otosclerosis is a progressive disease causing stapes fixation and conductive hearing loss. While tympanometry and high-resolution computed tomography (HRCT) are commonly used for diagnosis, their accuracy varies. This study evaluates the diagnostic performance of these modalities individually and in combination, using intraoperative findings as the reference standard.

**Methods:** A retrospective analysis of 40 patients who underwent exploratory tympanotomy for suspected otosclerosis was conducted. Preoperative tympanometry and HRCT findings were compared to intraoperative confirmation. Sensitivity, specificity, positive predictive value (PPV), and negative predictive value (NPV) were calculated. McNemar's test assessed statistical significance.

**Results:** Tympanometry had high sensitivity (78.13%) but low specificity (50%), whereas HRCT had lower sensitivity (43.75%) but higher specificity (62.6%). Combining both improved specificity (75%) but reduced sensitivity (37.5%). PPV remained high (85.7% for the combined test), indicating substantial predictive value when both tests were positive. However, NPV was consistently low, limiting their reliability in ruling out otosclerosis. Statistical analysis showed no significant change in diagnostic accuracy when combining tests.

**Conclusion:** Tympanometry is helpful for screening, while HRCT aids in confirmation. However, neither test, alone nor in combination, reliably excludes otosclerosis due to low NPV. Preoperative HRCT interpretation should involve experienced radiologists, and emerging imaging techniques may enhance diagnostic accuracy.

**Keywords:** Conductive Hearing Loss, High Resolution Computed Tomography, Otosclerosis, Tympanometry.

## INTRODUCTION

Otosclerosis is a disorder of bony remodelling in which the otic capsule endochondral bone, which is dense, is replaced by spongy bone, which later hardens and leads to fixation of stapes.<sup>1</sup> These patients usually present with conductive hearing loss with intact tympanic membrane; however, sometimes sensory component can be seen when the cochlea or round window is involved. Preoperative evaluation includes clinical examination, audiological evaluation with Pure Tone Audiometry (PTA), and Tympanometry routinely with optional radiological evaluation with Resolution Computed Tomography (HRCT). The reduction in compliance identified as As type of curve in tympanometry and Carhart's notch in PTA are recognised as common signs in otosclerosis and are routinely performed in all cases as they are non-invasive compared to HRCT, which involves radiation exposure.<sup>2</sup> While the sensitivity of HRCT in diagnosing otosclerosis

ranges from 45-75% in different studies,<sup>3,4</sup> it is being performed in various centres routinely as a pre-operative mode of investigation. This study aims to assess the ability of HRCT to predict otosclerosis with and without in conjunction with audiological modalities.

**Senior Resident<sup>1</sup>, Junior Resident<sup>2</sup>, Assistant Professor<sup>3</sup>, Associate Professor<sup>4,5</sup>, Additional Professor<sup>6</sup>, Professor<sup>7</sup>**

Department of Otorhinolaryngology<sup>1,4,6-7</sup>

Department of Diagnostic & Interventional Radiology<sup>5</sup>

All India Institute of Medical Sciences, Jodhpur

**Corresponding Author:** Amit Goyal

Professor and Head, Department of Otorhinolaryngology

All India Institute of Medical Sciences, Jodhpur

**Email ID:** meetugoyal@yahoo.com

**Source of funding:** None

**Conflict of interest:** None declared

This is an open access journal, and articles are distributed under the terms of the Creative Commons Attribution-NonCommercial-ShareAlike 4.0 License, which allows others to remix, tweak, and build upon the work non-commercially, as long as appropriate credit is given and the new creations are licensed under the identical terms.

**For reprints contact:** sabarish@krishers.com

**How to cite this article:** Siddharth M, Advait B Rashmi H, Vidhu S, Sarbesh T, Kapil Soni, Amit G. Evaluating the Diagnostic Accuracy of Tympanometry and High-Resolution CT in Otosclerosis: A Retrospective Comparative Study. J Otolaryngol Head Neck Surg. 2025; 1(1):1-4

Access this article online	
<b>Website:</b> <a href="https://ajohns.net/">https://ajohns.net/</a>	<b>Quick Response Code</b>
<b>DOI:</b> ???????	

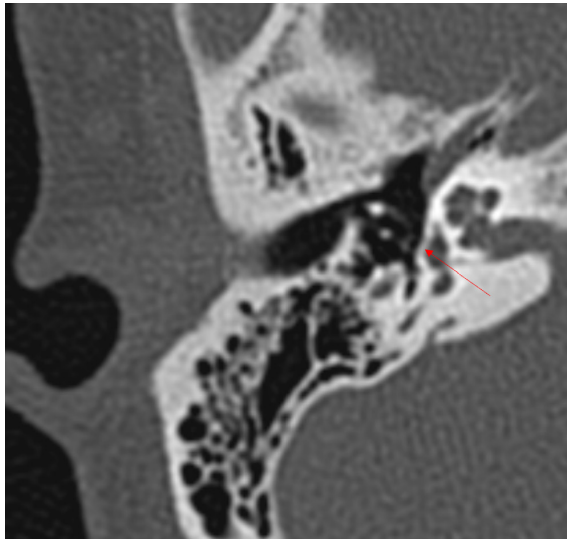
## METHODOLOGY

A retrospective chart review was performed for adult patients with Suspected Otosclerosis who underwent Exploratory Tympanotomy over 5 years, between January 2020 and December 2024, at a tertiary care hospital in Western Rajasthan (Department of Otorhinolaryngology, All India Institute of Medical Sciences, Jodhpur).

Data were collected using Hospital records. Patients were deemed eligible for inclusion if they were 18 years of age or older and underwent Exploratory Tympanotomy following both preoperative Tympanometry and HRCT temporal bone scan. Patients were excluded if there was no Tympanometry, preoperative HRCT scan, or had a history of chronic suppurative otitis media, prior ear surgery, ipsilateral temporal bone trauma, or congenital middle or inner ear anomalies.

**Surgical Technique:** The surgeries were performed under 2 senior specialists in the department by Endaural or Postaural approaches. The ossicular chain was palpated to check for mobility. If the Stapes was found to be fixed, stapedotomy was performed. In other cases, respective management was performed.

**Analysis of Radiologic Interpretation -** A dedicated high-resolution CT temporal bone scan with 0.6 mm axial slice thickness through the temporal bone without contrast was ordered. The scans were then reviewed in a Clinico-radiological meeting between the operating surgeons and a senior radiologist with particular interest in Neuroradiology.



**Figure 1:** High Resolution Computed Tomography (HRCT) Temporal Bone demonstration demineralisation at stapes foot plate (Fissula ante fenestrum)

## RESULTS

**Demographic Characteristics -** The average age of patients at the time of surgery was  $40.0 \pm 10.2$  years (range 18 to 59 years). 20 patients (50 %) were female, and 20 were male (50%), representing a 1:1 ratio.

**Laterality Data -** Left and right ears were affected at similar rates, with 46% and 54% involvement, respectively. Bilateral disease occurred in 60%, and the remaining 40% had unilateral involvement.

Among the 40 patients, A type of curve was found in 29 (72.5%) patients, and other curves were found in 11 patients (Table 1). 17 out of 40 patients were reported to have sclerotic foci in pre-operative HRCT (42.5%) (Table 3). Intraoperative, 32 patients (80%) were found to have stapes fixation, and the rest 8 were not found to have stapes fixation (Table 1 & 3). 14 patients (35%) showed positive findings in both (As type curve in Tympanometry and sclerotic foci in HRCT) (Table 5). The sensitivity, specificity, Positive Predictive Value (PPV), and Negative Predictive Value (NPV) were calculated for Tympanometry (Table 2), HRCT (Table 4) individually and for both (Table 6).

From these tables, we can see the decrease in Sensitivity and increase in Specificity when the tests are combined. To check the significance of this change, McNemar's Test was applied. The critical value was  $\chi^2 (1.67) < 3.84$  for specificity and  $\chi^2 = 0$  for sensitivity, which suggests that the observed change is not significant for the sample size of 40.

**Table 1:** Tympanometry vs Intra-operative Finding

	Otosclerosis Present	Otosclerosis Absent	Total
As Type curve on Tympanometry	25	4	29
Other curves on Tympanometry	7	4	11
<b>Total</b>	32	8	40

**Table 2:** Tympanometry vs Intra-operative Finding – Statistical Analysis

Sensitivity	78.13%
Specificity	50%
Positive Predictive value	86.21%
Negative Predictive value	36.36%

**Table 3:** HRCT vs Intra-operative finding

	Otosclerosis Present	Otosclerosis Absent	Total
HRCT Could detect	14	3	17
HRCT Couldn't detect	18	5	23
<b>Total</b>	32	8	40

**Table 4:** Tympanometry vs Intra-operative Finding – Statistical Analysis

Sensitivity	43.75%
Specificity	62.6%
Positive Predictive value	82.35%
Negative Predictive value	21.75%

**Table 5:** HRCT + Tympanometry vs Intra-operative finding

	Otosclerosis Present	Otosclerosis Absent	Total
Both Tests Positive	12	2	14
Both Tests Negative	20	6	26
Total	32	8	40

**Table 6:** HRCT + Tympanometry vs Intra-operative Finding – Statistical Analysis

Sensitivity	37.5%
Specificity	75%
Positive Predictive value	85.7%
Negative Predictive value	23.1%

## DISCUSSION

The study evaluates the diagnostic performance of Tympanometry, High-Resolution Computed Tomography (HRCT), and their combined use in detecting otosclerosis, using intraoperative findings as the reference standard. The results demonstrate the strengths and limitations of each modality.

### 1. Tympanometry vs. Intraoperative Findings

**Sensitivity:** 78.13% → Tympanometry can correctly identify stapes fixation in 78.13% of cases.

**Specificity:** 50% → Tympanometry can misclassify 50% of patients without stapes fixation.

**Positive Predictive Value (PPV):** 86.21% → A positive As-type curve on tympanometry strongly suggests stapes fixation.

**Negative Predictive Value (NPV):** 36.36% → A non-A tympanometry curve does not reliably exclude stapes fixation. This suggests Tympanometry is highly sensitive but moderately specific in diagnosing otosclerosis. The high PPV suggests that if an As-type curve is present, there is a strong likelihood of otosclerosis. However, its low specificity and NPV mean that an alternative tympanometry result does not reliably rule out the disease, leading to false negatives.

### 2. HRCT vs. Intraoperative Findings

**Sensitivity:** 43.75% → HRCT can detect stapes fixation in only 43.75% of confirmed cases.

**Specificity:** 62.6% → HRCT can rule out stapes fixation in 62.6% of cases.

**PPV:** 82.35% → A positive HRCT finding strongly suggests stapes fixation.

**NPV:** 21.75% → A negative HRCT does not exclude stapes fixation.

### Interpretation:

HRCT has lower sensitivity compared to tympanometry, meaning it misses more cases of otosclerosis. This is much the same as reported in US populations<sup>4</sup> and much lesser than mentioned in European populations.<sup>5</sup> However, it has higher specificity, reducing the number of false positives, but it is still lower than mentioned by Kanzara et al.<sup>6</sup> The PPV is high, meaning a positive HRCT scan strongly supports otosclerosis. However, its low NPV indicates that a negative scan does not reliably exclude the condition.

### 3. Combined Tympanometry + HRCT vs. Intraoperative Findings

The combined assessment improves specificity (75%) but at the cost of reducing sensitivity (37.5%). This means that while the test is better at avoiding false positives, it misses more true cases of otosclerosis. The high PPV (85.7%) suggests that if both tests are positive, otosclerosis is very likely.

However, the low NPV (23.1%) indicates that if both tests are negative, otosclerosis still cannot be ruled out confidently.

## OVERALL CLINICAL IMPLICATIONS

Tympanometry alone is more sensitive but has lower specificity. It is useful for screening otosclerosis, but its false positive rate limits its standalone diagnostic value.

HRCT alone is less sensitive but has higher specificity. It is better at confirming otosclerosis rather than detecting it.

The combined assessment improves specificity but significantly reduces sensitivity. While it minimizes false positives, it misses more true cases, making it less reliable for ruling out otosclerosis.

The difference in radiological reporting was also discussed between well-trained and less-trained individuals, which demands the review of radiology by a senior radiologist.<sup>7</sup> We impel on the need for a discussion between the surgeon and radiologists before the surgery for better clarification. The usage of densitometry and other quantitative measures, as mentioned by Sha et al.,<sup>8</sup> should also be under consideration for better outcomes from HRCT.

## CONCLUSION

Neither HRCT nor tympanometry alone is sufficient for the preoperative diagnosis of otosclerosis. For screening otosclerosis, Tympanometry alone is more effective. For confirming otosclerosis, HRCT or the combined test is preferred. For ruling out otosclerosis, none of the tests reliably exclude the condition due to their low NPV. However, HRCT remains useful in atypical cases, complex anatomical variations (overlying facial nerve, aberrant stapedia artery),

and revision surgeries, while tympanometry serves as a valuable. Advances in imaging techniques, machine learning-assisted analysis, and standardized radiological interpretation may enhance preoperative detection in the future.

## REFERENCES

1. Zafar N, Hohman MH, Khan MA. Otosclerosis. In: StatPearls [Internet]. Treasure Island (FL): StatPearls Publishing; 2025 [cited 2025 Mar 2]. Available from: <http://www.ncbi.nlm.nih.gov/books/NBK560671/>
2. Danesh AA, Shahnaz N, Hall JW. The Audiology of Otosclerosis. *Otolaryngologic Clinics of North America*. 2018 Apr 1;51(2):327–42.
3. Min JY, Chung WH, Lee WY, Cho YS, Hong SH, Kim HJ, et al. Otosclerosis: Incidence of positive findings on temporal bone computed tomography (TBCT) and audiometric correlation in Korean patients. *Auris Nasus Larynx*. 2010 Feb;37(1):23–8.
4. Maxwell AK, Shokry MH, Master A, Slattery WH. Sensitivity of High-Resolution Computed Tomography in Otosclerosis Patients undergoing Primary Stapedotomy. *Ann Otol Rhinol Laryngol*. 2020 Sep;129(9):918–23.
5. Naumann I, Porcellini B, Fisch U. Otosclerosis: Incidence of Positive Findings on High-Resolution Computed Tomography and Their Correlation to Audiological Test Data. *The Annals of otology, rhinology, and laryngology*. 2005 Oct 1;114:709–16.
6. Kanzara T, Virk J. Diagnostic performance of high resolution computed tomography in otosclerosis. *World Journal of Clinical Cases*. 2017 Jul 16;5:286.
7. Bassiouni M, Bauknecht HC, Muench G, Olze H, Pohlan J. Missed Radiological Diagnosis of Otosclerosis in High-Resolution Computed Tomography of the Temporal Bone—Retrospective Analysis of Imaging, Radiological Reports, and Request Forms. *JCM*. 2023 Jan 12;12(2):630.
8. Zhu M mei, Sha Y, Zhuang P yun, Olszewski A, Jiang J qi, Jiang J, et al. Relationship between high-resolution computed tomography densitometry and audiometry in otosclerosis. *Auris, nasus, larynx*. 2010 Dec 1;37:669–75.