

# Approach to a Case of Otogenic Cerebellar Abscess

Sauradeep Das<sup>1</sup>, Nayana Sarma<sup>2</sup>, Prachurya Tamuli<sup>3</sup>, Suvamoy Chakraborty<sup>4</sup>

Received on: 27 February 2025; Accepted on: 03 April 2025; Published on: 07 April 2025

## ABSTRACT

Chronic otitis media (COM) is a common ear infection leading to multiple intracranial and extracranial complications. But with the advent of antibiotics, the rate of complications has reduced. Intracranial complications are a dreaded result of such infections, and the rarity of such complications has rendered their treatment a rarity, often reported as isolated case reports. Here we would like to discuss a case of a 20 year old male with cerebellar abscess due to Chronic Otitis Media (COM), along with postauricular abscess and post aural discharge which was treated surgically with mastoid exploration along with concurrent neurosurgical intervention followed by medical management with antibiotic and anticoagulant coverage with complete recovery of the patient. The patient was observed to have a complete recovery with no residual abscess. Three months postoperative follow-up of the patient revealed a healed mastoid cavity with an intact neotympanum. Even though rare and moribund, when treated properly, patients recover completely.

**KEYWORDS:** otogenic cerebellar abscess, intracranial complication, chronic otitis media, mastoid exploration, multidisciplinary approach.

## INTRODUCTION

Chronic otitis media (COM) is a persistent ear infection that leads to various complications, including cerebellar abscess. This is a rare but serious complication of COM.<sup>1</sup> Studies have shown that, in developing countries, the incidence of otogenic intracranial complications, including cerebellar abscess, is still high.<sup>2-3</sup> Children are particularly vulnerable to these complications and also are at a higher risk of developing intracranial abscesses.<sup>2</sup> The incidence of otogenic cerebellar abscess is low, with a reported rate of 0.2-0.8% of all intracranial abscesses.<sup>4</sup> The management of otogenic brain abscesses is a complex process that requires a multidisciplinary approach.<sup>5</sup> In many cases, it involves a combination of surgical and medical management, including craniotomy and mastoidectomy.<sup>6</sup> In recent years, concurrent craniotomy and mastoidectomy have been on trend for the treatment of otogenic intracranial abscesses.<sup>6</sup>

## CASE REPORT

In this case, a 20-year-old male came with complaints of left ear discharge and hearing loss for 4 years with recent onset of painful left-sided postaural swelling for 1 week, which ruptured 2 days later, with yellowish, purulent, foul-smelling

discharge. The discharge from the left ear was similar in characteristics. The patient also complained of headaches with no history of fever, seizures, or loss of consciousness. On examination, the patient was conscious and well-oriented and had stable vitals.

On local examination, the right ear was normal. The left postauricular region was swollen with multiple pus-discharging sinuses, with erythema of surrounding skin. There was a local rise of temperature with the presence of tenderness. On examination of the left external auditory canal, granulation tissue was noted covering the whole of the tympanic membrane. On pure tone audiometry (PTA), the left ear had 90 dBHL, with profound mixed hearing loss with normal hearing on the right ear.

**Senior Resident<sup>1,3</sup>, Post Graduate Trainee<sup>2</sup>,  
Professor and Head of Department<sup>4</sup>,**

**Corresponding Author:** Nayana Sarma  
Post Graduate Trainee,

Department of ENT, NEIGRIHMS  
Shillong – 793018

**Email:** nayanas402@gmail.com

**Source of funding:** None

**Conflict of interest:** None declared

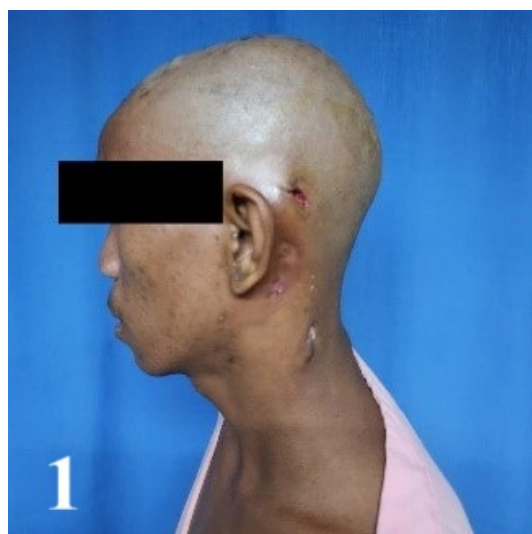This is an open access journal, and articles are distributed under the terms of the Creative Commons Attribution-NonCommercial-ShareAlike 4.0 License, which allows others to remix, tweak, and build upon the work non-commercially, as long as appropriate credit is given and the new creations are licensed under the identical terms.

**For reprints contact:** sabarish@krishers.com

**How to cite this article:** Sauradeep D, Nayana S, Prachurya T, Suvamoy C.. Approach to a Case of Otogenic Cerebellar Abscess . J Otolaryngol Head Neck Surg. 2025; 1(1):18-21

### Access this article online

Website:	Quick Response Code
<a href="https://ajohns.net/">https://ajohns.net/</a>	
DOI: ???????	

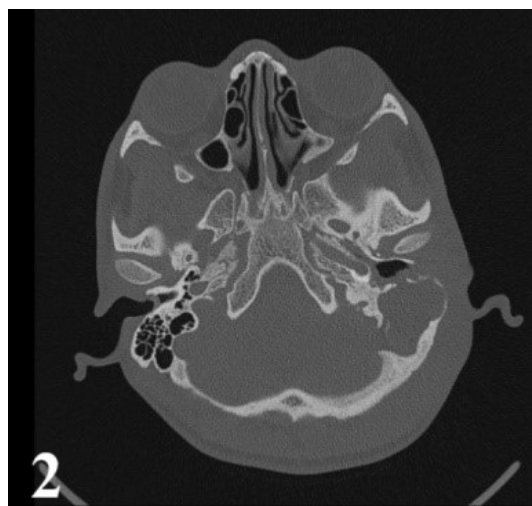


**Figure 1:** Shows preoperative image of the patient's postaural region with postaural sinus

The patient was incidentally found to be diabetic on admission with a random blood glucose of 221 mg/dL and HbA1c = 7.7%. The patient was started on Regular Insulin along with empirical antibiotic coverage for his primary symptoms.

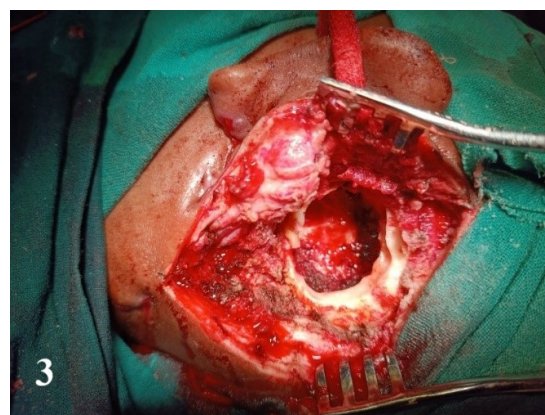
Pus from the left postaural region reported the presence of *Proteus mirabilis* sensitive to most of the antibiotic groups. All routine blood investigations were carried out, which revealed an elevated total leucocyte count of 13000/cumm with hemoglobin of 12.8 g%. Other investigations were within normal limits.

The patient was planned for an urgent contrast-enhanced computed tomography (CECT) head and neck, which revealed a hypo-enhancing collection centred in the mastoid segment of the left temporal bone with intracranial extension into the posterior cranial fossa, causing buckling of the underlying cerebellar hemisphere.



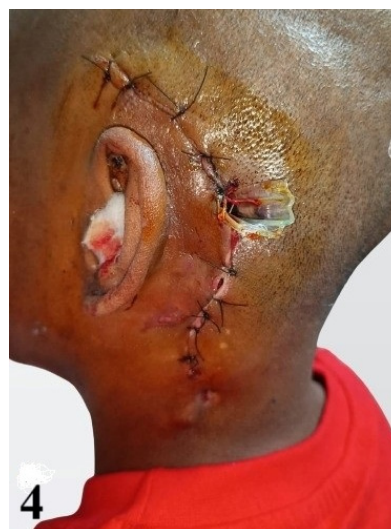**Figure 2:** This shows a cut section of CECT of the temporal bone showing left-sided mastoid abscess communicating to the posterior cranial fossa

After 3 days of conservative management of his primary symptoms and control of blood sugar levels, the patient was taken up for exploration of the mastoid with consultation with the neurosurgery department. Left Modified Radical Mastoidectomy (MRM) with type IV tympanoplasty with conchomeatoplasty was done along with cerebellar abscess drainage and drain placement in the same sitting. Intraoperatively, cholesteatoma was seen extending from the mastoid antrum posteriorly up to the cerebellum, inferiorly to the tip of the mastoid. The Dura of the cerebellum was exposed along with the temporal lobe. The Tegmen plate and facial canal were found to be dehiscence, along with the posterior external auditory canal wall. All ossicles were absent except the footplate of stapes.



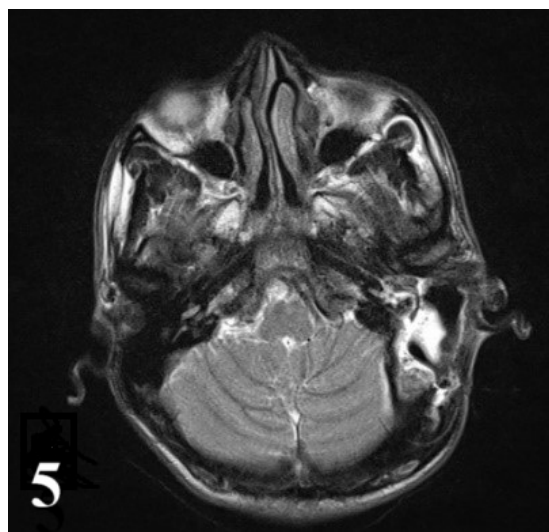
**Figure 3:** Shows an intraoperative image exposing the dura of cerebellum

Postoperatively, the patient was given antibiotics based on the culture and sensitivity report. The drain was removed on the third postoperative day. Regular dressing was done with all aseptic and antiseptic precautions, and gradually, the healing was noted in 2 weeks after surgery.



**Figure 4:** This shows an image of the patient's left postaural region surgical scar with an indwelling drain on postoperative day 2.

A Contrast-Enhanced Magnetic Resonance Imaging (CE-MRI) of the brain was done on POD 15, which revealed post-MRM status with soft tissue density suggestive of gelfoam kept intraoperatively.



**Figure 5:** Shows a cut section of postoperative CE-MRI brain showing soft tissue density suggestive of postoperative cavity filled with gelfoam and temporalis muscle.

The patient was discharged on POD 17 on oral antibiotics. The patient was reviewed on OPD basis 1-month post-discharge, in which the patient was symptomatically better with intact neotympanum on operated ear. PTA was repeated 3 months after surgery, which showed an improvement of 22 dBHL on the operated side.

## DISCUSSION

COM is a common disease that, when untreated, can cause both extracranial and intracranial complications. Cerebellar abscess is a rare but potentially life-threatening complication of COM. According to a study by Sharma et al., of 12 years of experience in a single institute, intracranial (IC) complications occurred in 2.3–4% of cases before the antibiotic era. With antibiotics and new surgical techniques, the complications have been greatly reduced to 0.15–0.04 % with an incidence of otogenic cerebellar abscess of 0.2–0.8% of all intracranial abscesses.<sup>4,7</sup> Mortality decreased from 25% to 8 %.<sup>7</sup>

COM can be due to bacterial or fungal infection in the middle ear.<sup>7</sup> Otogenic cerebellar abscess is thought to be caused by the spread of infection from the middle ear to the brainstem or cerebellum through the cranial nerve foramina.<sup>8</sup> Previous literatures have reported that brain abscess is more commonly located in the cerebrum, i.e temporal lobe, than in the cerebellum. However, recent studies, for instance, reported by Dubey and Larawin et al., found that otogenic brain abscesses are more commonly seen in the cerebellum.<sup>1</sup>

In cases of cerebellar abscess, patients may present with signs of increased intracranial pressure, such as headache, nausea, vomiting, altered sensorium, ataxia, nystagmus, and other

neurological deficits.<sup>3,10</sup> In our case, the patient presented with a long-term history of left ear discharge associated with decreased hearing, for which he did not take any treatment previously. The patient came following complications in the form of a left postaural abscess and severe headaches for 1 week.

The diagnosis of an otogenic cerebellar abscess is based on a combination of clinical examination, imaging studies, and microbiological analysis.

Culture and sensitivity tests of ear discharge or brain abscess aspirates are important to identify the causative organism and guide in the selection of antibiotics.<sup>6</sup> In a study, 41 patients with otogenic brain abscesses were examined, which reported the most commonly found microorganism as *Proteus*.<sup>9</sup> Similarly, in our case, in post-aural abscess pus sent for culture, the growth of *Proteus mirabilis* was noted.

CT and MRI are the most commonly used radiological investigations.<sup>1</sup> With a diagnostic rate of 92.75%, a CT scan is very helpful in the diagnosis of otogenic intracranial complications.<sup>1</sup>

The treatment of otogenic cerebellar abscess requires surgical intervention along with antibiotic coverage. Mastoidectomy and drainage of the middle ear are usually performed to remove the source of the infection, and craniotomy may be needed to drain the abscess.<sup>6</sup> The choice of antibiotics should be guided by culture and sensitivity results, and the treatment should be adjusted as necessary based on the patient's clinical response.<sup>10</sup> Our patient, after 2 days of conservative management with empirical antibiotic coverage, was taken up for surgery and Left Modified Radical Mastoidectomy along with cerebellar abscess drainage was done.

The necessity of immediate mastoidectomy (within 24 to 48 hours) with neurosurgical drainage of the abscess is emphasized by some authors to reduce mortality and enhance the treatment effects of antibiotics.<sup>1</sup>

The type of causative organism, the extent of the infection, and the patient's immune status affect the outcome of the disease and its management. Full recovery is seen in the majority of the patients with appropriate treatment, but permanent neurological sequelae may occur in some cases.<sup>1</sup>

## CONCLUSION

Otogenic cerebellar abscess is a rare but serious complication of COM. The management of this condition requires a prompt and coordinated approach that involves surgical intervention with neurosurgical intervention and intraoperative assistance, antibiotics, and drainage of the infected site. The incidence of COM and its associated complications remains high in many developing countries, highlighting the need for improved public health measures and better access to medical care. The exact pathophysiology of otogenic cerebellar abscess is still not fully understood, and there is a need for further research in this area.

## REFERENCES

1. Zainuddin N, Mohd Khalid MS. A Case of Chronic Otitis Media Complicated with Cerebellar Abscess. *Bangladesh J Med Sci*. 2018 Jan 11;17(1):149–51.
2. Jain A, Arora N, Meher R, Passey JC, Bansal R. Intracranial complications of CSOM in pediatric patients: A persisting problem in developing countries. *International Journal of Pediatric Otorhinolaryngology*. 2017 Sep;100:128–31.
3. Ahmad RU, Ashraf MF, Qureshi MA, Shehryar M, Tareen HK, Ashraf MA. Chronic Suppurative Otitis Media leading to cerebellar brain abscess, still a problem in 21st century: A case report. *Ann Med Surg (Lond)*. 2022 Jul 31;80:104256.
4. Duarte MJ, Kozin ED, Barshak MB, Reinshagen K, Knoll RM, Abdullah KG, et al. Otogenic brain abscesses: A systematic review. *Laryngoscope Investig Otolaryngol*. 2018 Apr 25;3(3):198–208.
5. Dubey SP, Larawin V. Complications of Chronic Suppurative Otitis Media and Their Management: The Laryngoscope. 2007 Feb;117(2):264–7.
6. Kurien M, Job A, Mathew J, Chandy M. Otogenic Intracranial Abscess: Concurrent Craniotomy and Mastoidectomy—Changing Trends in a Developing Country. *Arch Otolaryngol Head Neck Surg*. 1998 Dec 1;124(12):1353–6.
7. Kum RO, Özcan M, Ulusal T, Dündar G, Yılmaz YF, Ünal A. A Rare Complication of Chronic Otitis Media: Cerebellar Abscess. *Turk Arch Otorhinolaryngol*. 2017 Sep;55(3):140–3.
8. Gendeh HS, Abdullah A binti, Goh BS, Hashim ND. Intracranial Complications of Chronic Otitis Media: Why Does It Still Occur? *Ear Nose Throat J*. 2019 Aug 1;98(7):416–9.
9. Sennaroglu L, Sozeri B. Otogenic brain abscess: review of 41 cases. *Otolaryngol Head Neck Surg*. 2000 Dec;123(6):751–5.
10. Sunnynchan S, Deshmukh P, Gaurkar SS, Panicker A, Vijayappan A. Otogenic Brain Abscess: Judicious Management in a Case of Chronic Suppurative Otitis Media. *Cureus [Internet]*. 2022 Oct 18 [cited 2023 Jan 7].