

NASALACTINOMYCOSIS MIMICKING JUVENILE NASOPHARYNGEAL ANGIOFIBROMA- A RARE CASE REPORT

Authors:

Dr. Kalpana Sharma¹, Dr. Uma Roy², Dr. Kumkum Bora³, Dr. Navroz Mehta²

¹Professor, ²Post Graduate Trainee, ³Associate Professor

Department of Otorhinolaryngology and Head and Neck Surgery,
Gauhati Medical College, Guwahati, Assam, India

ABSTRACT: Nasal Actinomycosis is a rare chronic infectious disease of nose and paranasal sinuses. Here, we present 16-year-old boy with recurrent nasal bleed and nasal obstruction for 2 years. On DNE and posterior rhinoscopy, reddish mass seen in left nasal cavity, choana and nasopharynx. He appeared pale and anaemic. CT findings suggested JNA. But HPE established a diagnosis of Actinomycosis infection. Endoscopic excision of mass was done with coblator under general anaesthesia. Post operative period was uneventful. This case report is being highlighted for its rarity and unusual presentation.

INTRODUCTION:

Actinomycosis caused by *Actinomyces* spp is a chronic granulomatous infection. These are filamentous, gram-positive, non-acid fast and facultative anaerobic bacteria. These are part of normal microflora.^[1] The etiologic agents include *Actinomyces israelii* (most common), *Actinomyces naeslundii*, *Actinomyces odontolyticus*, and *Actinomyces viscosus*. The incidence is 1 case in 300,000.^[1] It affects all ages (mostly 20-50 years) with male preponderance (Male: Female = 3:1). Actinomycosis is classified into three clinical forms: Cervicofacial: (most common) 50-70%. Thoracic: 15-20% and Abdominopelvic: 10-20%.^[2-5] Nasal cavity involvement in cervicofacial region is extremely rare. Cervicofacial actinomycosis frequently affects maxillary sinus.^[6] It causes swelling of cheek with woody induration and draining sinus tracts. Isolated lesions of tongue, salivary glands, infratemporal fossa and larynx have been reported. Poor dental hygiene is the most frequently reported risk factor for cervicofacial actinomyces infection.^[4,13,15] Chronic gingivitis, dental procedures and other chronic disorders of oral cavity increase risk. It can lead to abscess formation, osteomyelitis or osteonecrosis. Diagnosis is done by histopathological examinations showing Actinomyces Colonies and Sulfur Granules and also, by Culture.^[3,4,16] Surgical Excision and Long-term Antibiotic Therapy is the treatment.^[5-8] Antibiotics that are prescribed are Penicillin (antibiotic of choice), Ceftriaxone, Amoxicillin, Clindamycin, Macrolides and Doxycycline. Treatment dosages and duration vary from 2 weeks to several months depending on severity of disease and treatment response.^[4-7] In this paper, we report a case of nasal cavity involvement with actinomyces, proven in histologic studies, who was managed with surgical excision and intravenous antibiotics.

CASE REPORT:

A 16-year-old boy presented with recurrent episodes of epistaxis for 2 years. It was profuse, spontaneous, painless and relieved on medication. He also had left-sided nasal blockage for 1 year. It was intermittent and progressive. He had poor oral hygiene. On Anterior Rhinoscopy and Nasal Endoscopy, a reddish mass with pale areas was seen in left nasal cavity. There was no pain or bleeding on touch. Nasal septum was deviated to right side. On Posterior rhinoscopy a reddish mass with variegated surface was found in choana and nasopharynx.

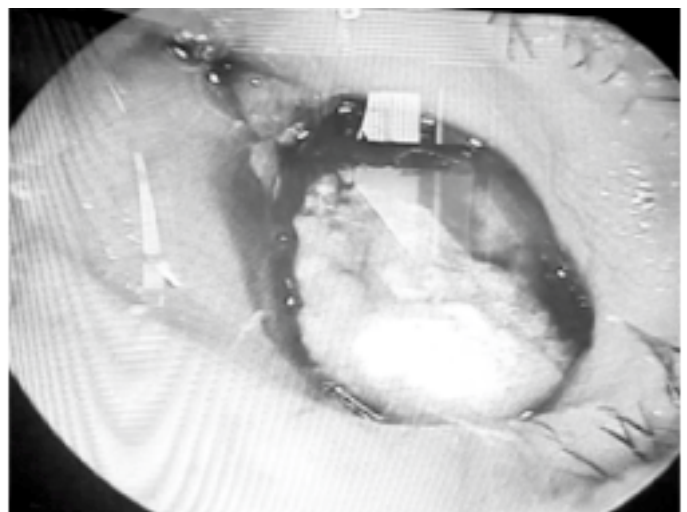


FIG 1: ANTERIOR RHINOSCOPY

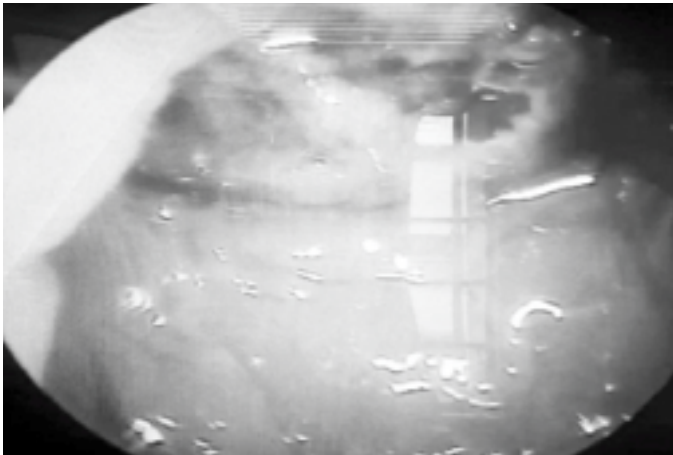


FIG 2: POSTERIOR RHINOSCOPY

On General Examination, boy was conscious but appeared pale. His vital signs were as follows- BP: 100/70 mmHg.Pulse: 88 beats/min.Temperature: 98.7° F.Blood investigations showed Hemoglobin= 6.5g/dL and other parameters were normal.

CT scan showed Well defined heterogeneous lesion in left sphenopalatine foramen extending to left maxillary sinus, nasal cavity and nasopharynx suggesting Juvenile Nasopharyngeal Angiofibroma.

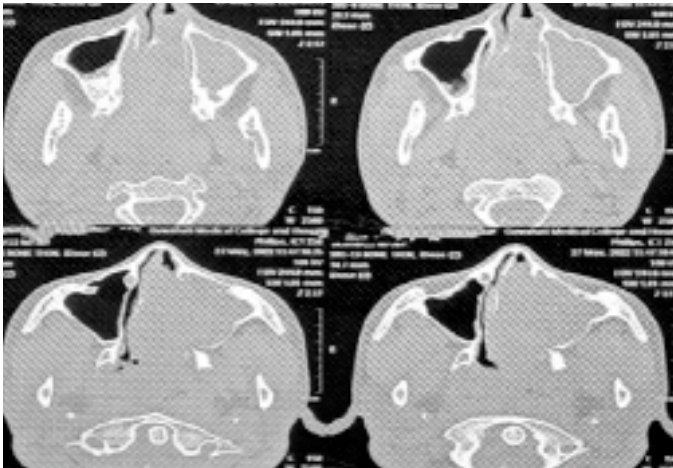


FIG 3: Axial sections of CT NOSE AND PNS of the patient

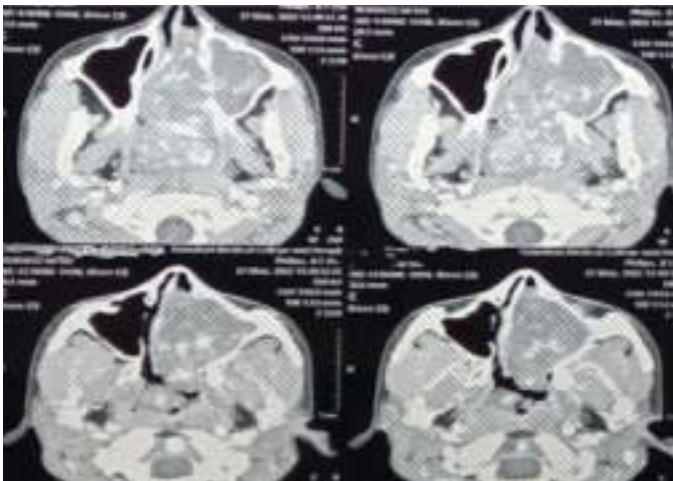


FIG 4: Axial sections of CECT NOSE AND PNS of the patient

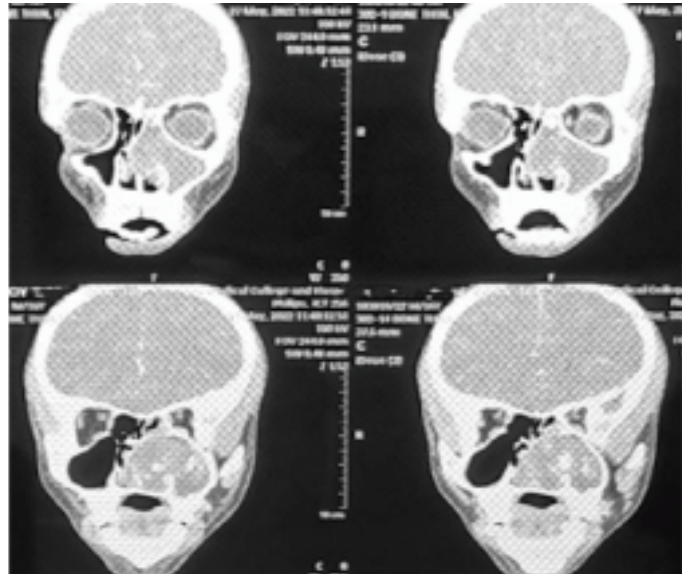


FIG 5: Coronal sections of CECT NOSE AND PNS

Initially patient was started on IV Ceftriaxone and tranexamic acid and 3 units Packed Red Blood Cells were transfused.

As there was no bleeding during the hospital stay, under all precautions and preparations it was decided to take biopsy from nasal mass. HPE revealed Multiple deeply basophilic granular aggregates (sulphur granules). Granular colonies of actinomycosis surrounded by eosinophilic branching filaments (SPLENDORE HOEPLI). Abundant necrotic material seen and suggested Actinomycosis infection. IHC was not proposed.

Endoscopic excision of mass done with coblator under general anaesthesia. This was combined with course of ceftriaxone followed by oral Amoxycyclon on discharge.

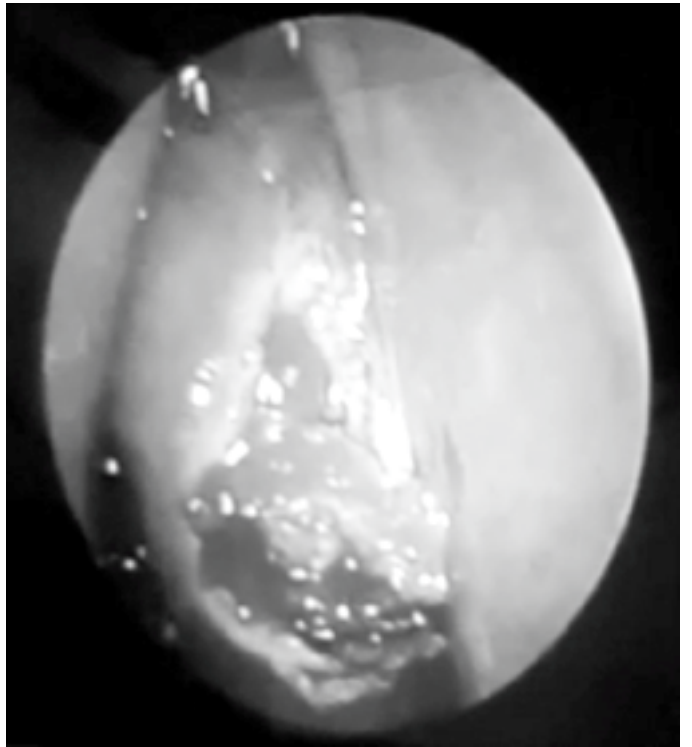


FIG 6

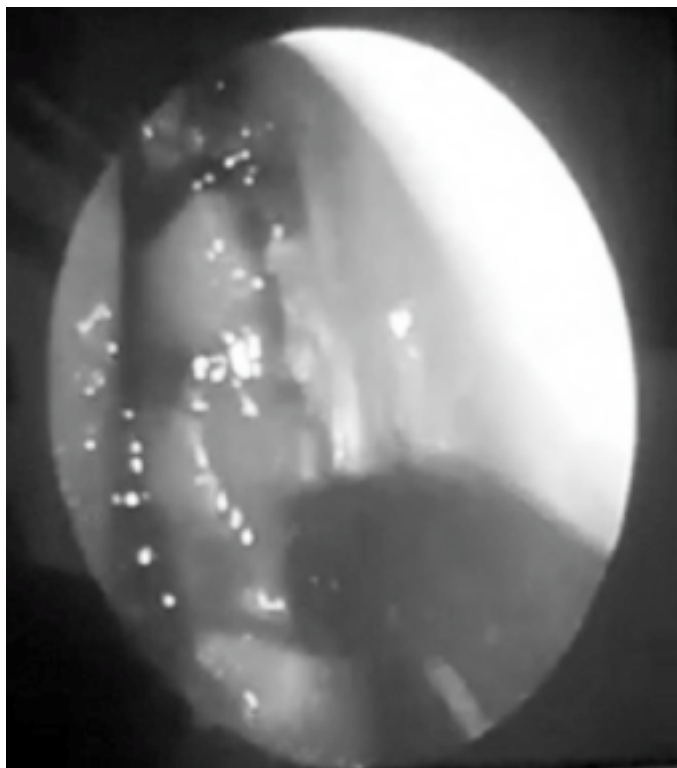


FIG 7

FIG 6 and 7: Intraoperative pictures

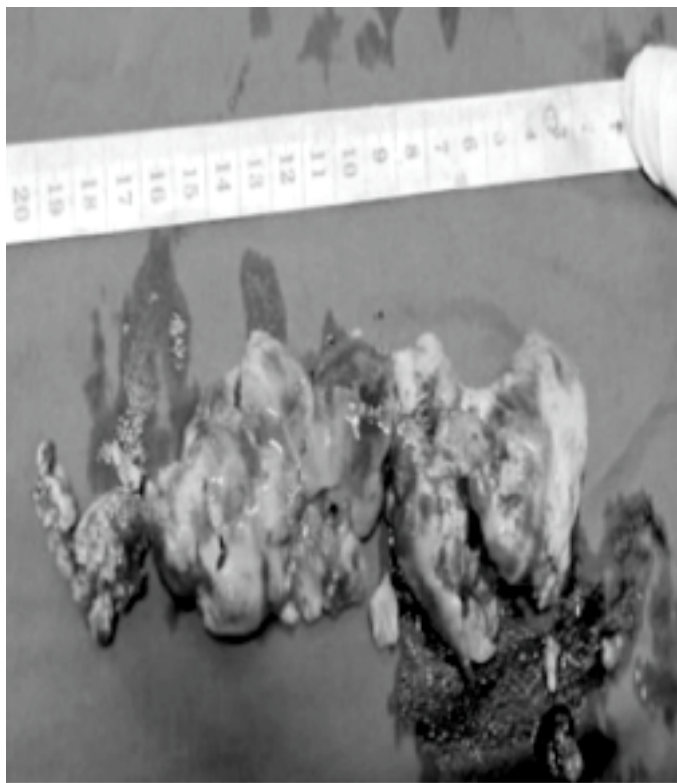


FIG 8

FIG 8: specimen

Follow-up Nasal endoscopy after 2 weeks postop was normal. Post-op HPE confirmed the diagnosis.

DISCUSSION:

Nasal Actinomycosis is rare. In our case, initial symptoms of recurrent epistaxis with sinonasal mass in an adolescent boy were consistent with JNA. Only predisposing factor was poor oral hygiene.

Daamen et al, Randal et al, Baliga et al, Ozcan et al^[2-5]; in their study found that nasal actinomycosis can present with purulent nasal discharge, foul odor, anosmia or headache. It should be suspected when chronic sinusitis (mainly maxillary sinus), does not respond to medical therapy. It can be difficult to distinguish between new involvement with actinomyces and recurrent sinus infections. Pathologic evaluation is necessary to avoid misdiagnosis that can change course of therapy.

Study by Cohn et al.^[9] suggest that history of tooth extraction is important. Any discharge or odor from extraction site and maxillary tenderness should be examined.^[9,15]

As described in study by Saibene et al, Sinus actinomyces infection might look like malignant disease initially and confirmatory work-up are required.^[10]

Nasal actinomyces infection can also mimic Fungal Infection (Nasal Mucormycosis).^[12] It can also mimic nasal mucocele.^[11]

A study by Kim et al^[7] shows nasal actinomyces can also present with prolonged change in smell and purulent nasal discharge. Nasal actinomyces can also affect patients without any remarkable laboratory findings or lymphadenopathy and mimic foreign body.^[8]

CT of nasal actinomycosis show opacities in paranasal sinus, focal calcifications or bone destruction.^[7-10] Microbiologic and histopathologic findings make definitive diagnosis. Culture of Actinomyces is difficult. The presence of sulfur granules is pathognomonic of actinomycosis. Absence of granules does not rule it out as granules reside deep in tissues and reported in only 40 % of cases.^[14,15] Therefore, diagnosis of nasal actinomycosis is based on clinical examination, microbiologic or histopathologic findings, and sulfur granules.^[16]

CONCLUSION

Nasal actinomycosis should be taken into differential diagnosis when imaging studies show an expansive mass in nasal cavity with significant bony erosion for initiation of appropriate and early treatment, despite its rarity. The diagnosis of actinomyces should always be kept in mind when patient presents with poor dental hygiene, which raises suspicion of this infection. Prognosis for nasal actinomycosis is good. Long-term follow-up is necessary because infection can recur even after several years.

CONSENT

Written and informed consent was obtained from the patient regarding the use of the patient's picture and the reports of the investigations that were conducted.

CONFLICT OF INTEREST

The authors declare no conflicts of interest during the course of the making of this paper.

ETHICAL CLEARANCE

Ethical clearance was taken.

REFERENCES

1. Solduzian M, Hosseinpourfeizi A, Jafari-Rouhi AH, Pourkarim F. Nasal Actinomyces in a 7-year-old Boy with Recurrent Nasal Bleeding: A Case Report. *Hemoglobin (g/dL)*. 2022;8:11-6.
2. Daamen N, Johnson JT. Nasopharyngeal actinomycosis: A rare cause of nasal airway obstruction. *Laryngoscope* 2004;114(8):1403-5.
3. Randall D. The nose and paranasal sinuses. In: Lee KJ (ed). *Essential Otolaryngology: Head and Neck Surgery*. 8th edition. USA: The McGraw-Hill Companies; 2003:682-723.
4. Baliga S, Shenoy S, Wilson G, Katara V. An unusual case of actinomycosis. *Ear Nose Throat J* 2002;81(1):44-5.
5. Ozcan C, Talas D, Görür K, et al. Actinomycosis of the middle turbinate: An unusual cause of nasal obstruction. *Eur Arch Otorhinolaryngol* 2005;262(5):412-1
6. Lee DH, Lim SC. Actinomycosis of the nasal cavity. *Brazilian Journal of Otorhinolaryngology*. 2023 Jan 13;88:128-32.
7. Kim SD, Kim DS, Choi KU, Cho KS. Nasal cavity actinomycosis mimicking rhinolith. *Journal of Craniofacial Surgery*. 2018 May 1;29(3):e255-7.
8. Batzakakis D, Karkos PD, Papouliakos S, Leong SC, Bardanis I. Nasal actinomycosis mimicking a foreign body. *Ear Nose Throat J* 2013;92:E14-6.
9. Cohn JE, Lentner M, Li H, Nagorsky M. Unilateral Maxillary Sinus Actinomycosis with a Closed Oroantral Fistula. *Case Rep Otolaryngol* 2017; 2017:7568390.
10. Saibene AM, Di Pasquale D, Pipolo C, Felisati G. Actinomycosis mimicking sinonasal malignant disease. *BMJ Case Rep* 2013; 2013:bcr2013200300.
11. Lee DH, Yoon TM, Lee JK, Lim SC. Nasal septum actinomycosis mimicking mucocele. *Journal of Craniofacial Surgery*. 2020 Mar 1;31(2):e147-9.
12. Gupta V, Dwivedi G, Sengupta P, et al. A rare case of sinonasal actinomycosis - enigmatic presentation. *Int J Otorhinolaryngol Head Neck Surg* 2018; 4:863-7
13. Sakuma Y, Yamashita Y, Shiono O, Oridate N. Actinomycosis arising from the nasal cavity, with rare fatal progression. *BMJ Case Rep* 2016; 2016:bcr2015213747
14. Könönen E, Wade WG. Actinomyces and related organisms in human infections. *Clin Microbiol Rev* 2015; 28:419-42.
15. Moghimi M, Salentijn E, Debets-Ossenkop Y, Karagozoglu KH, Forouzanfar T. Treatment of cervicofacial actinomycosis: a report of 19 cases and review of literature. *Med Oral Patol Oral Cir Bucal* 2013; 18:e627-32.
16. Acevedo F, Baudrand R, Letelier LM, Gaete P. Actinomycosis: a great pretender. Case reports of unusual presentations and a review of the literature. *Int J Infect Dis* 2008; 12:358-62.