Submental Flap in Small but Reconstructive Mandated Oral Cavity Lesions

Chanmiki Sayoo

Received on: 24 March 2025; **Accepted on:** 28 March 2025; **Published on:** 07 April 2025

ABSTRACT

In this era of microvascular reconstruction, where the practise of microvascular surgery is widely practised by many surgeons, reconstruction with free flap has become mandatory in most of the head and neck oncological procedures. However, due to its difficult learning curve and time-consuming nature, free flaps are not routine surgery for many surgeons. The success of free tissue transfer surgery is not solely determined by the surgeon's skills alone. Age and operative time can cause medical complications, if not surgical complications, and hence can lead to free flap failure.

There are some lesions where local and regional flaps still hold their value as a good substitute for free flaps. The submental flap is one such flap. Though the utility and safety of the submental flap in oncological surgery has been questioned by many, with proper case selection and proper technique, the submental flap is still good and safe in oral cavity reconstruction.

The purpose of this paper is to present a series of 13 patients who had undergone reconstruction with submental flaps after resection of their primary tumours in the oral cavity.

Key words: Oral cancer, reconstruction, submental flap

INTRODUCTION

Cancer of the oral cavity includes cancer of the lips, hard palate, soft palate, retromolar trigone, front two-thirds of the tongue, gingiva, buccal mucosa, and floor of the mouth.[1] Globally, oral cancer is the sixth most common cancer.[2] In India, around 77,000 new cases and 52,000 deaths are reported annually, which is approximately one-fourth of the global incidence. As compared to the West, 70% of oral cancers in India are detected in the advanced stage (American Joint Committee on Cancer, Stage III and IV). Due to this late detection, the overall five-year survival rate is only around 20%. However, with early detection (stage I or II), the five-year survival can increase from 50% to 80%.[4]

The management of oral cancer includes surgery, radiotherapy, and chemotherapy. Surgery remains the primary treatment approach.[5] Surgery involves removal of a tumour with a margin of at least 1-1.5cm along with neck dissection accordingly.[6]

Resection of the tumour usually leaves a surgical defect that mandates reconstruction for cosmetic and functional purposes. Options for reconstruction include split-thickness skin graft, loco-regional flap, and free flap. Skin grafts may be useful for superficial defects but have their limitations. Regional flaps (pectoralis major, dectopectoral, lattisimus dorsi) are the most reliable flaps but have the disadvantage of being too bulky and may not match the required result. Other flaps, like nasolabial and platysma, have been used, but they are unreliable or of limited versatility in terms of coverage of oral cavity defects.[7]

Free flaps such as radial forearm and anterolateral thigh flaps have become the reconstruction of choice in the majority of medium to large defects in the oral cavity. However, they need trained personnel and microsurgical set up and are usually associated with increased surgical time, which may lead to medical complications after surgery.[8]

Access this article online	
Website: **https:**//ajohns.net/	**Quick Response Code**
DOI: 10.66243/Krishers-AJOHNS-002	

Corresponding Author: Chanmiki Sayoo, MS

Consultant

Department of Otorhinolaryngology Head and Neck Surgery, Woodland Hospital, Shillong, Meghalaya- 793003

Email ID: csayoo@gmail.com

Source of funding: None

Conflict of interest: None

This is an open access journal, and articles are distributed under the terms of the Creative Commons Attribution-NonCommercial-ShareAlike 4.0 License, which allows others to remix, tweak, and build upon the work non-commercially, as long as appropriate credit is given and the new creations are licensed under the identical terms.

For reprints contact: sabarish@krishers.com

How to cite this article: Chanmiki Sayoo. Submental Flap in Small but Reconstructive Mandated Oral Cavity Lesions. J Otolaryngol Head Neck Surg. 2025; 1(1):5-9

Over the last few years, the submental flap has gained popularity for reconstruction in oral cavity defects.[9] The operative time and hospital stay are shorter compared to the gold standard radial forearm free flap and do not require highly trained personnel and microsurgical set up. These factors make the submental flap a reconstruction of choice in properly selected cases.

PATIENTS AND METHODS

A total of 13 patients, 5 females and 8 males, were operated on for squamous cell carcinoma of their oral cavity by a single surgeon from January 2020 to December 2024. The patients' age ranges from 32 years to 60 years. The site of the tumour location is shown in table 1:

Table 1:

Location of tumour	Number of patients
Tongue	4
Floor of mouth	1
Angle of mouth	1
Buccal mucosa	4
Lower lip	2
Alveolus of mandible	1
Total	13

The size of all these tumours at the time of operation was not more than 4 cm (TNM Staging T2), and none of them had lymph nodes radiologically at the submental region (Level Ia). All the tumours are lateralised, and none of them are located at or crossing the midline.

SURGICAL TECHNIQUE

The patient was made to lie supine with a shoulder extension. A pinched test was performed to delineate the maximum width of the flap. The elliptical island incision marking is made under the submental area, as shown in Fig 1. The length of the flap can extend from one angle of the mandible to the other, depending on the requirement. The approach to harvest a submental flap has been described differently by different authors, but the one that is described here is the approach that is routinely used by the author of this article.

The incision is made as shown in Fig 2 (red line). The subplatysmal flap is then elevated, preserving the marginal mandibular branch. Dissection continued with careful dissection of the submandibular gland by avoiding injury to the common facial vein. Bipolar cautery with a pointed tip is recommended at this stage, as monopolar cautery can cause thermal damage to the submental vessels. Branches of the facial artery to the submandibular gland are ligated, and the gland is then removed. The pedicle of the flap can be seen after removing the submandibular gland, as shown in Fig 3.

Figure 1: Marking

Figure 2: Incision marking

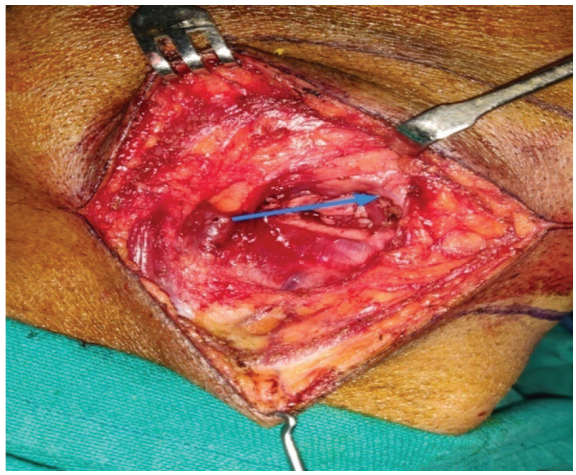

Figure 3: Pedicle shown by arrow

The next step is to extend the incision by following the marking 1.5 cm below the mandible at the midline. Dissection is then continued from the other end of the flap till the contralateral anterior belly of the digastric muscle is seen. The anterior belly of the ipsilateral digastric muscle is then divided from its mandibular attachment and separated from the mylohyoid muscle below and opposite digastric muscle (anterior belly) as shown in Fig 4. A stay suture is then placed between the edge of the flap and the anterior belly of the digastric muscle to prevent unnecessary shearing of the flap. Dissection is then continued towards the pedicle, keeping the muscle and skin as one unit. The digastric muscle is then divided from its common tendon, and the flap is ready and tested for its viability, as shown in Fig 5. The flap can now be transferred into the oral cavity either beneath the mandible, where tunnelling has to be done by removing the mylohyoid muscle, or above the mandible.

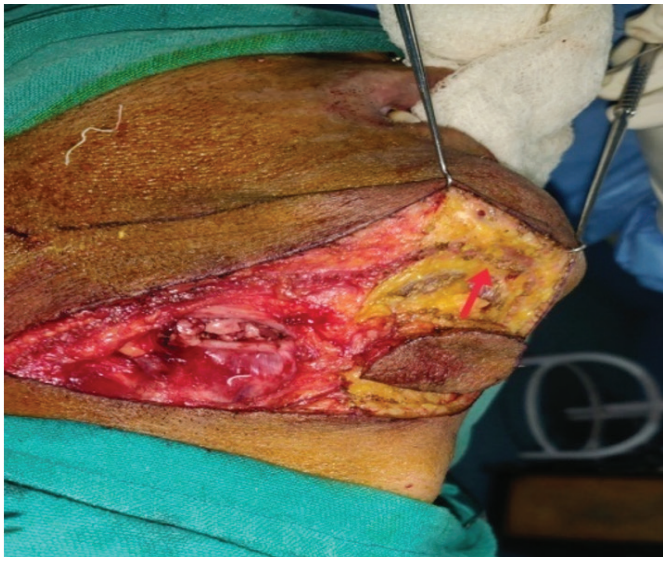

Figure 4: Red arrow indicates mid line between anterior belly of digastric muscle

Figure 5: Flap tested for its viability by cutting the edge

RESULT

All patients underwent one-stage resection of the primary tumour, neck dissection, and reconstruction of the surgical defect with the submental flap. The site of the primary lesions are mentioned in Table 1. Selective neck dissection removing lymph nodes of level I to III were performed in 9 patients and other 4 patients (Tongue as primary lesion), lymph nodes clearance of level I to IV was done. In all the patients, the flap was of ipsilateral to the primary tumour. In six patients, the pedicle was on the left side, and in seven patients, the pedicle was on the right side.

The average operative time to harvest the flap was 30 minutes. The presence of the pedicle does not cause hindrance or delay the neck dissection duration.

In all the patients, the flap was successfully harvested. Postoperatively, two patients experienced venous congestion of the flap on the next postoperative day. The flap eventually necrosed in these two patients and was discarded; one was buccal mucosa, and the other was the angle of the mouth. The buccal mucosa defect was left to granulate, and the angle of mouth defect was closed by Abbe-Estlander flap on the fourth postoperative day. In all other patients, the flap was viable till the latest date of follow-up.

The profile of the two patients that experienced failure of the flap was, one was a fat lady with thick subcutaneous fat that requires reconstruction for her defect in buccal mucosa. In the other patient, the flap was transposed to the angle of the mouth defect over the mandible without tunnelling or removing the subcutaneous tissue of the skin over the mandible.

Some of the pre-, intra-, and post-operative lesions are shown below in figures 6, 7, and 8:

Pre operative Post operative

Figure 6: Growth Lower lip

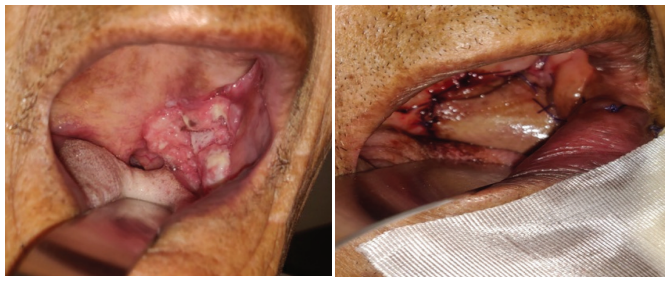

Pre operative Post operative

Figure 7: Growth Buccal

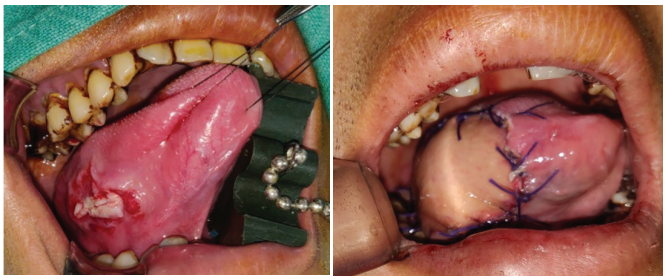

Pre operative Post operative

Figure 8: Growth Tongue

DISCUSSION

The submental flap was first reported in 1993 by Martin et al.[10] It is based on the submental artery, a constant branch of the facial artery. The short duration of harvesting, well vascularised and non-sophisticated requirement of microsurgical set has made this flap a good choice in most of the reconstruction in oral cavity. In non-oncological cases, this flap has found its wide application.

The submental flap could be classified according to blood supply as a pedicled flap, free flap, or perforator flap and, according to the composition of the flap paddle, as a myocutaneous or osteocutaneous flap.[11] The submental pedicle flap can be pedicled inferiorly, i.e., orthograde variant, or superiorly, i.e., reverse flow variant. The orthograde variant is based on the facial artery, and the reverse flow variant relies on the anastomosis between the external and internal carotid arteries via the angular artery. In this series, the author has used the orthograde variant in all the cases.

The inclusion of the anterior belly of digastric muscle with the flap is controversial. Yetman[12] and Magden et al[13] found that the main submental artery courses beneath the anterior belly of digastric muscle in most specimens. However, there is also a superficial branch that runs above the digastric muscle. Indeed, the survival of the flap has not been affected by omitting the muscle.[14] In this series, the author has included the anterior belly of the digastric muscle with the flap in all the cases. Including the muscle with the flap may certainly increase the viability of the flap, but in some cases, it may cause difficulty in transposing the flap to the oral cavity due to its added thickness. To increase the perforating vessels and venous drainage, part of the mylohyoid muscle can also be included with the flap.

Chow et al.[15] reported partial loss of 2 out of 10 flaps. Marten et al.[16] reported loss of one flap in 11 non-irradiated patients. The latter author recommended avoiding using this flap in a patient who had received radiotherapy to the neck. In this series, there was a complete loss of two flaps. From the author's experience, factors that can contribute to the loss of the flap include: thick neck or thick subcutaneous tissue, compression of the pedicle beneath or over the mandible. Proper tunnelling beneath or above the mandible can prevent compression of the pedicle.

There has been concern in the literature about the oncological safety of this flap as harvesting this flap can compromise the lymph node clearance or may result in the spreading of the tumour to the recipient area. However, dissection in the subplatysmal plane, as recommended by Chow et al., would minimise the chance of inadequate clearance or tumour spread. Amin et al. prescribed the complete lymph node dissection before flap harvesting and recommend that this flap should be avoided in clinically positive node.[17]

In this series, 5 patients underwent adjuvant radiotherapy after surgery. The reason for adjuvant radiotherapy was perineural invasion in the final histopathological finding in 3 patients, depth of invasion more than 5mm in one patient, and level II node positive in one patient. Till the last follow-up, the flap in all the patient who received or didn't receive radiotherapy is viable except in those two patients who had loss of flap in immediate post op day, and as far as the last follow-up is concern there is no sign of recurrent disease in both the primary and the neck.

CONCLUSION

Due to the long duration of surgery and highly trained surgeon required for free flap reconstruction, the submental flap still holds its value in small defect reconstruction in the oral cavity after resection of early-stage tumours. Proper case selection is necessary before choosing the submental flap for reconstruction.

REFERENCES

1. P.H. Montero, S.G. Patel. Cancer of the oral cavity. Surg Oncol Clin N Am, 24 (3) (2015), pp. 491-508, 10.1016/j.soc.2015.03.006
2. Sung H, Ferlay J, Siegel RL, Laversanne M, Soerjomataram I, Jemal A, et al. Global cancer statistics 2020: GLOBOCAN estimates of incidence and mortality worldwide for 36 cancers in 185 countries. CA Cancer J Clin 2021;71:209–49. Laprise, Claudie, et al. "Periodontal diseases and risk of oral cancer in Southern India: Results from the HeNCe Life study." International journal of cancer 139.7 (2016): 1512-1519.
3. Veluthattil, Aswin Chandran, et al. "Effect of hypofractionated, palliative radiotherapy on quality of life in late-stage oral cavity cancer: a prospective clinical trial." Indian Journal of Palliative Care 25.3 (2019): 383.
4. Lokhande Monika, Kannusamy Sivaranjini, Oak Amey, Cheulkar Sandhya, Chavan Shalmali, Mishra Varsha, Gode Pragati, Thakadiyil Aijimol S, Mendhe Saket, Kadam Supriya, Balasubramaniam Ganesh, Chaturvedi Pankaj, Dikshit Rajesh (2024) A hospital-based study of survival in oral cancer patients of Tata Memorial Hospital, Mumbai ecancer 18 1669
5. Shaw, Richard J., John Edward O'Connell, and Mandeep Bajwa. "Basic surgical principles and techniques." Textbook of Oral Cancer: Prevention, Diagnosis and Management (2020): 253-282

6. D'Cruz AK, Vaish R, Kapre N, Dandekar M, Gupta S, Hawaldar R, Agarwal JP, Pantvaidya G, Chaukar D, Deshmukh A, Kane S, Arya S, Ghosh-Laskar S, Chaturvedi P, Pai P, Nair S, Nair D, Badwe R; Head and Neck Disease Management Group. Elective versus Therapeutic Neck Dissection in Node-Negative Oral Cancer. N Engl J Med. 2015 Aug 6;373(6):521-9. doi: 10.1056/NEJMoa1506007. Epub 2015 May 31. PMID: 26027881.

7. Squaquara, Roberto, et al. "Intraoral reconstruction using local and regional flaps." Seminars in plastic surgery. Vol. 24. No. 02. © Thieme Medical Publishers, 2010.

8. Kesting, M.R., Hölzle, F., Wales, C. et al. Microsurgical Reconstruction of the Oral Cavity with Free Flaps from the Anterolateral Thigh and the Radial Forearm: A Comparison of Perioperative Data from 161 Cases. Ann Surg Oncol 18, 1988–1994 (2011). https://doi.org/10.1245/s10434-011-1584-8.

9. Sebastian, Paul, et al. "The submental island flap for reconstruction of intraoral defects in oral cancer patients." Oral oncology 44.11 (2008): 1014-1018.

10. D. Martin, J.F. Pascal, J. Baudet, J.M. Mondie, J.B. Farhat, A. Athoum, P. Le Gaillard, G. Peri. The submental island flap: a new donor site. Anatomy and clinical applications as a free or pedicled flap. Plast. Reconstr. Surg., 92 (5) (1993 Oct), pp. 867-873.

11. Rahpeyma, Amin, and Saeedeh Khajehahmadi. "Submental artery island flap in intraoral reconstruction: a review." Journal of Cranio-Maxillofacial Surgery 42.6 (2014): 983-989.

12. Faltaous, Adel A., and Randall J. Yetman. "The submental artery flap: an anatomic study." Plastic and reconstructive surgery 97.1 (1996): 56-60.

13. Magden, Orhan, et al. "Anatomic study of the vasculature of the submental artery flap." Plastic and reconstructive surgery 114.7 (2004): 1719-1723.

14. Kim, Jeong Tae, et al. "An anatomic study and clinical applications of the reversed submental perforator-based island flap." Plastic and reconstructive surgery 109.7 (2002): 2204-2210.

15. Chow, Tam-Lin, et al. "Reconstruction with submental flap for aggressive orofacial cancer." Plastic and reconstructive surgery 120.2 (2007): 431-436.

16. Merten, S. L., R. P. Jiang, and David Caminer. "The submental artery island flap for head and neck reconstruction." ANZ journal of surgery 72.2 (2002): 121-124.

17. A.A. Amin, M.A. Sakkary, A.A. Khalil, M.A. Rifaat, S.B. Zayed The submental flap for oral cavity reconstruction: extended indications and technical refinements. Head. Neck Oncol., 3 (2011 Dec 20), p. 51